

Single Stage Primary Cheiloalveoloplasty and Open Tip-Plasty in Complete Bilateral Cleft Lip & Palate Without Nasoalveolar Molding

AMIR ELBARBARY, M.D.

The Department of Plastic Surgery, Faculty of Medicine, Ain-Shams University

ABSTRACT

The surgical management of bilateral cleft nasal deformity remains a functional & aesthetic dilemma for the reconstructive plastic surgeon. The development of presurgical orthopedics/nasoalveolar molding facilitated lip closure & improved nasal projection. Unfortunately, in the developing countries, nasoalveolar molding is not widely available to serve all BCLP patients. A number of techniques have been developed to reposition the lower lateral cartilage domes at the time of lip repair & recruit columellar skin from nasal tip skin instead of prolabium. Among these is the one-stage open rhinoplasty at the time of lip repair which allows for the best possible exposure to the displaced dome cartilages and avoids scars at both the nasal tip & lip-columella junction.

Primary alveolocheiloplasty has been our standard of care for the cleft patients. In this study, we report successful combination of cheiloalveoloplasty & primary open tip-plasty with modifications at six months of age in 21 infants suffering bilateral complete cleft lip & palate followed-up to three & half years. Nasal tip projection and columellar length of these patients were comparable to age matched controls at one year postoperatively.

Despite the lack of nasoalveolar molding, a well-implemented primary lip, alveolar & open tip-plasty is cost effective in limiting the number of surgical interventions & combining the advantages of both cheiloalveoloplasty & open tip-plasty. It stabilizes the alveolar segments and eliminates the occurrence of anterior palatal & alveolar fistulae by providing a two-layer closure. Furthermore, this approach provides optimally oriented nasal tip anatomy while reducing the social stigma of the bilateral cleft lip nose appearance early during the child's growth.

INTRODUCTION

The premaxilla is not attached to the lateral palatal shelves in the complete bilateral cleft lip. It is unrestrained in its forward movement because of septal cartilage growth and fetal tongue movements. The anterior nasal spine is either small or absent, and the lateral piriform apertures are displaced laterally (Latham, 1973 [1] and King et al., 1979 [2]). The nasal deformity is closely related to the position of the premaxilla, prolabium, lateral maxillary segments, and to symmetry of the cleft.

Severe protrusion of the premaxilla adds to the complexity of the nasal deformity with the prolabium attached almost at the nasal tip with very little or no columella (Bardach et al., 1991) [3].

The primary dysmorphogenesis behind the bilateral cleft lip nasal deformity is both hypoplasia & deformation. The nasal lobule progressively deforms and the lower lateral cartilages distorts as the premaxilla continues to protrude in relation to the hypoplastic lateral maxillary segments (Fisher & Mann, 1998) [4]. The tip defining points of the nasal lobule separate and the infratip lobule becomes broad transversely and shortened sagittally. The deformation effectively splays the lower lateral cartilages resulting in lengthening the lateral crura and shortening the medial crura. Respectively the columella becomes gradually shorter. The angle between the medial and lateral crurae increases and the soft triangle broadens, becoming short in the anteroposterior dimension and laterally displaced. Additionally, the unopposed pull of the lateral lip musculature separates the alar bases (Panossian & Fisher, 2008) [5].

Repair of the bilateral complete cleft lip is characterized by a huge diversity of treatment protocols. One-stage versus two-stage repairs, preliminary lip adhesion, dissection of nasal cartilage, and presurgical orthopaedics/nasoalveolar molding are among the controversial issues. Nasoalveolar molding as popularized by Grayson et al. (1993) [6], adds a nasal extension made of acrylic to the palatal plate to improve tip projection. However, their results rely on compliance and on early onset of its use (Morovic et al., 2001 [7] and Grayson & Garfinkle 2009 [8]). Additionally, the burden of care may render nasoalveolar molding impractical; it requires time, close follow-up, an additional cost, and is not always available. Mulliken [9] believe that the nasal lining and cutaneous cover are preexpanded in the bilateral cleft lip and

that the preoperative nasal stretching is unnecessary. The conflicting data in the literature regarding its use raise the question of the true necessity for its integration within the treatment protocols [10] and Lee et al., 2008 [11]. Henry & associates [12] state that more studies are still needed to assess long-term outcomes after nasoalveolar molding and to compare them with patients undergoing only primary rhinoplasty at the time of lip repair.

Traditionally lip reconstruction has been done at the expense of the nose. Nasal correction was postponed for delayed or secondary procedures termed "columellar lengthening". These skin-based repairs utilize the excess width of the prolabial skin & push it up as forked flaps to create a columella at a second stage [13,14]. This resulted in a nasal deformity that looks worse following lip repair alone; with a broad flattened droopy nasal tip that appears attached to the prolabium with very little or no columella, slumped nostrils, and flared alae nasi. (Mulliken, 2004) [15]. The obvious stigmata of a bilateral cleft lip nose deformity have a tremendous negative impact on the emotional wellbeing as well as socially on these children while growing up Kramer et al., [16,17].

McComb [18,19] revolutionized bilateral care by bringing the splayed out domes of the lower lateral cartilage together in a normal anatomic relationship under direct vision in concert with a lip adhesion. He utilized a V-incision over the nasal tip that was closed in a V-Y advancement to elongate the columella. The final lip repair was done at a second stage. Mulliken [20] proposed the one stage repair based on bringing the lower lateral cartilages together by sutures through bilateral nostril apex rim incisions. A midline skin incision was utilized originally but was discarded later on to avoid the central scars over the nasal tip Mulliken [21]. In 1993, Trott & Mohan [22] introduced open rhinoplasty to approximate the domes at the time of lip repair. The prolabial flap is carried on the distal end of the columellar skin. Cutting [23] approximated the domes from behind through a retrograde method. He used a membranous septum incision approaching the domes from the septal angle. Furthermore, he employed presurgical nasoalveolar molding to reposition the premaxilla, and stretch the columella and nasal lining before surgery. Similarly, Talmant [24] utilized the retrograde approach but advocated postsurgical stenting to maximize the nasal results.

Recently, the general consensus has been that nasal repair should be done at the time of primary lip repair in the bilateral cleft infants and the

principles for single stage repair have been well established [12,25,26]. Interdomal sutures are placed between the lower lateral cartilages to narrow the tip and increase projection. The aim is to produce an aesthetically pleasing nose that falls within the normal anthropometric range and sustains a normal physiologic function. Ideally, the technique should offer low complication rate, little need for secondary corrective surgery or highly specialized appliances, minimal scarring that is hidden as much as possible, no interference with growth, and to be cost effective [27,28].

Undoubtedly, primary rhinoplasty with repositioning of the alar cartilage produces better outcomes. The predictability, long-term results and influences on growth, have been discussed by many authorities. Nakajima & colleagues [29] believe that it is desirable to conduct early lip and nose repair synchronously in a minimally invasive manner after their fifteen years of experience with simultaneous repair of bilateral cleft lip & nose. Careful surgical manipulation of the lower lateral cartilages have been proven not to cause any distortion nor stunts the growth of these structures [30]. Furthermore, long-term follow-up of patients having primary corrections of lower lateral cartilages reveals not only no nasal growth abnormalities but also a much more normal nasal shape [31-34].

Mulliken [15] stated that it is technically possible to repair synchronously a bilateral cleft lip and the nasal malformation, usually in conjunction with premaxillary gingivoperiosteoplasty. Primary alveolocheiloplasty according to Badran et al., technique [35] does not require presurgical orthopedics/nasoalveolar molding and has been our standard of care in primarily treating cleft lip & palate infants. Adding nasal tip repair at the time of lip repair has been a goal to improve the outcome of our patient population.

Aim of work:

The aim of this study is to report a technique that primarily combines cheiloalveoloplasty with an open nasal tip repair that has been modified without the use of presurgical orthopedics in the bilateral cleft lip & palate infants and to anthropometrically assess the nasal tip projection achieved.

PATIENTS AND METHODS

This prospective controlled study was conducted at the Plastic Surgery Department, Ain-Shams University, Cairo, Egypt between January 2011 and June 2014. It included infants with bilateral complete cleft lip & palate below the age of six

months presenting to the craniofacial outpatient clinic. Infants above the age of six months, those with incomplete bilateral clefts, or with previous attempts of lip or nasal repairs were excluded from the study.

All patients were thoroughly investigated pre-operatively. Standardized frontal, lateral & basal view photographs were taken within the limits of patients' cooperation according to their age. Direct anthropometric measurements of the nasal tip projection, columellar length, and columellar width were determined using a caliper according to Mullikan et al., (2001) [36] following intubation. Tip projection was measured from the lip-columella junction to the most projecting point on the nasal tip (subnasale-pronasale). Columellar length was demarcated from the lip-columella junction to the line connecting the most projecting point on the nostril rim on either side (subnasale-columella). Columellar width was calculated at the level of the midcolumella.

The operative procedure was conducted under general endotracheal intubation when infants reached six months of age. Lip, alveolar & anterior palate repair were done according to Badran et al. (2012) [35]. Simultaneous nasal tip repair was carried out during the same session according to Trott & Mohan (1993) [22] with some modifications. Briefly, the nasal tip was exposed through an open approach in a supraperichondrial plane with the columellar skin carrying the prolabial flap on its distal end (Fig. 1). The prolabial flap was first elevated off the premaxilla in a supraperiosteal plane. The dissection continued cephalad till reaching the columella. To ensure staying in the deep proper plane, the dissection in the nose was started laterally through a bilateral rim incision & preceded towards the nostril apex to become continuous with and join the columella-prolabial flap at the subdomal region exposing the entire nasal lobule. The fibroadipose tissue present between the domes was excised conservatively. The lower lateral cartilage domes were repositioned & held in place by PDS 5/0 sutures. The composite lip repair was finished keeping the prolabial flap narrower than the columella. This was accomplished by advancing a small v-flap from the lateral segment of the lip skin into the columella-prolabial flap to break straight line at the level of the columellar base at the nasal sill.

Patients were followed up to assess the surgical results of nasal tip repair for at least one year. The same intraoperative measurements were repeated at 3, 6 & 12 months postoperatively and were

compared to age matched controls. Statistical analysis of the collected data was done using the *t*-test with *p*-value considered significant when <0.05 .

RESULTS

Twenty-one patients with bilateral complete cleft lip & palate fulfilled the inclusion criteria & were included in the study. All patients postoperative period passed uneventful without any vascular compromise of the nasal tips, the columello-prolabial flaps, or the premaxillae. The alveolar segments were stabilized through out the follow up with no alveolar defects nor anterior palatal fistulae. The patients were followed-up to three & half years with a minimum follow-up of one year (Figs. 2,3). Neither healing abnormalities nor hypertrophic scars were found associated with the marginal rim incision.

Postoperative nasal tip projection (Table 1), and columellar length (Table 2) of these patients were comparable to age matched controls except for the columella which was found to be significantly longer in the operated group at 3 months of age. The columella was found to be significantly wider in the operated group when compared to age matched controls throughout all time intervals of the postoperative evaluations (Table 3).

Table (1): Nasal tip projection of the operated patients was found to be comparable to normal age-matched control group at 3, 6 & 12 months postoperatively.

	Operated	Controls	<i>p</i> -value
3 months	8.1±0.5	7.9±0.6	0.746
6 months	9.2±0.7	9.5±1.1	0.675
12 months	12.9±0.76	13.4±0.9	0.915

Table (2): The columella of the operated patients was found to be significantly longer than the age-matched control group at 3 months post to become comparable at 6 & 12 months postoperatively.

	Operated	Controls	<i>p</i> -value
3 months	6.3±0.52	5±0.4	0.045
6 months	6.9±0.4	6.5±0.5	0.708
12 months	8.3±0.57	8.2±0.7	0.658

Table (3): The columella of the operated patients was found to be significantly wider than the normal age-matched control group at 3, 6 & 12 months postoperatively.

	Operated	Controls	<i>p</i> -value
3 months	6.6±0.5	4.5±0.3	0.025
6 months	6.8±0.4	4.9±0.4	0.04
12 months	7.1±0.35	5.3±0.3	0.04

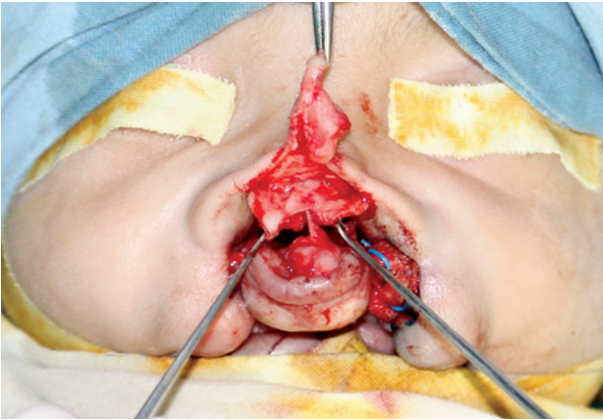
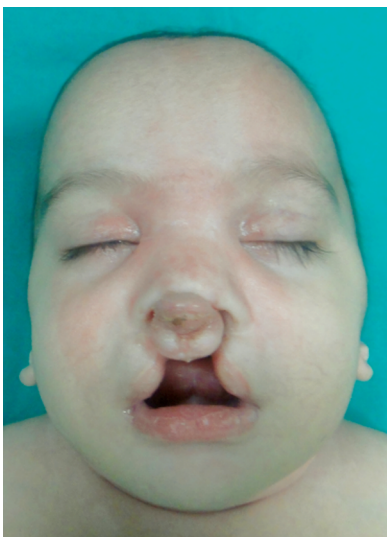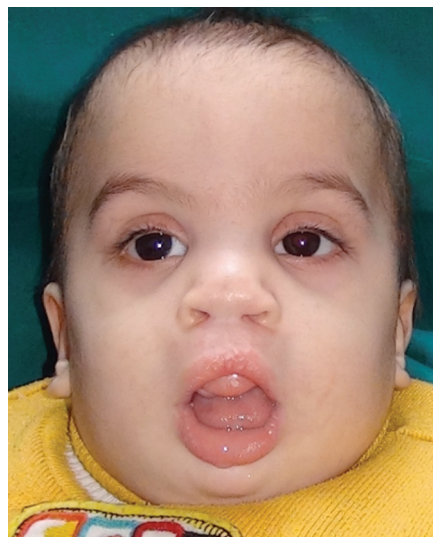


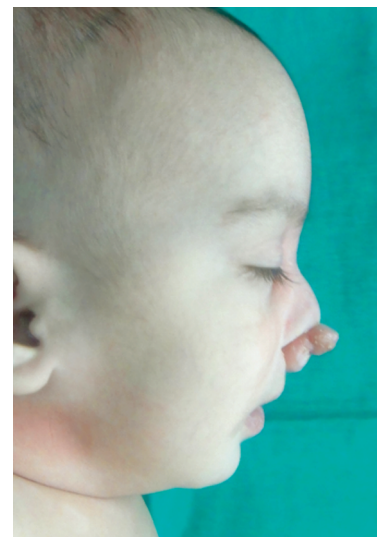Fig. (1): Intraoperative view demonstrating the open tip-plasty by elevating the prolabial flap based on the distal columellar skin to reposition the displaced lower lateral cartilage domes at the time of lip, alveolar & anterior palate repair in a 6-month-old infant with BCLP.



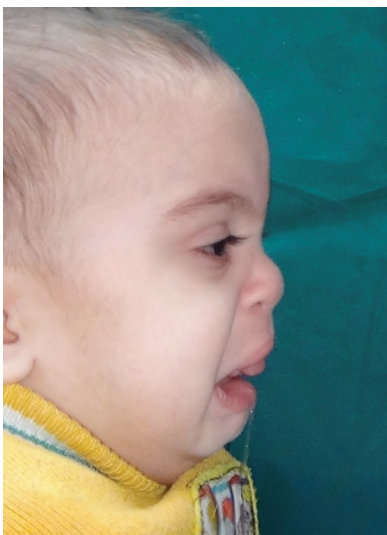(A)



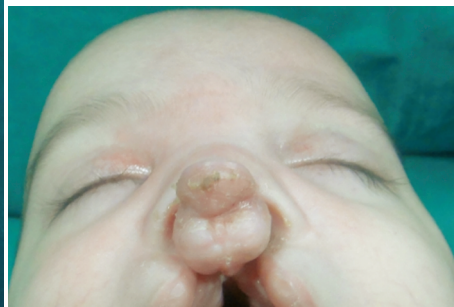(B)



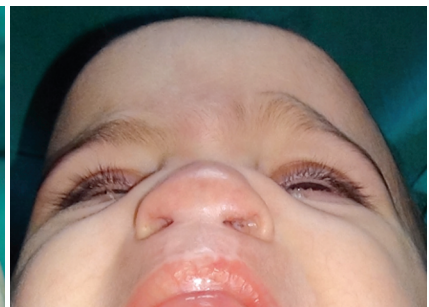(C)



(D)



(E)



(F)

Fig. (2): (A) Front view of a six-month-old male with bilateral complete cleft lip & palate & severe protrusion of the premaxilla. (B) Six months post demonstrating adequate tip production. (C) Same patient's profile view at six months of age with nasal tip appear attached to the prolabium & almost no columella is seen. (D) Six months post with adequate tip projection & columellar lengthening utilizing an open tip-plasty at the time of cheiloalveoplasty. (E) Base view demonstrating the severely protruding premaxilla away from the two lateral segments and (F) The restored nasal harmony at six months post with the apparent widening of the columella.

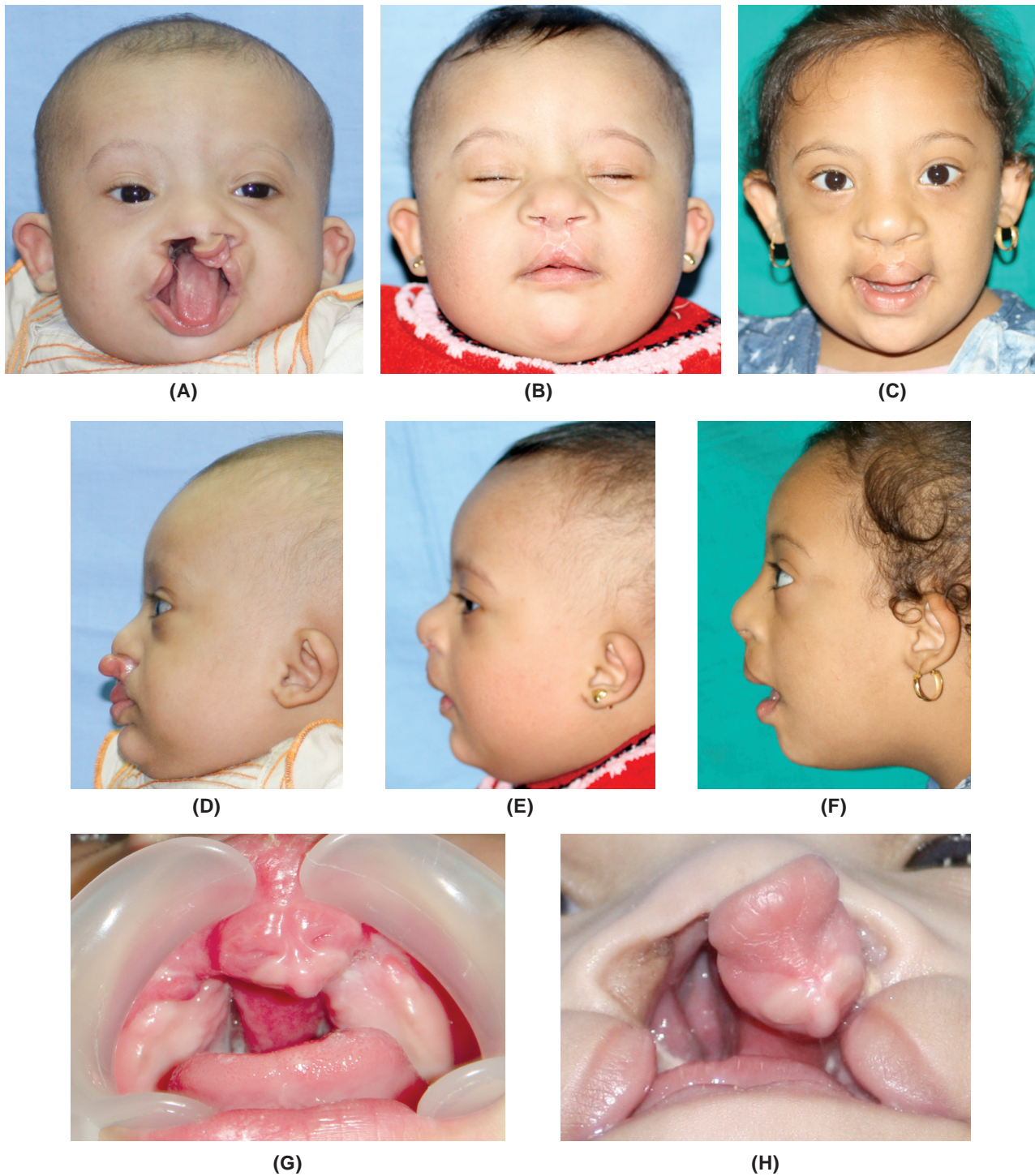

Fig. (3): (A) Front view of a six-month-old female with asymmetric form of bilateral complete cleft lip & palate. (B) Three months post and (C) Three & half years post were the open tip plasty is found to be advantageous over other techniques in restoring nasal symmetry. (D) Same patient's profile view at six months of age. (E) Three months post with adequate tip projection & columellar production (F) That was maintained over three & a half years post. (G) Oral view demonstrating the two lateral segments & the protruding premaxilla and (H) The sealed alveolus & anterior palate at three months post.

DISCUSSION

The two-stage skin based repairs that rely on the forked flaps tend to push the footplates of the medial crura up making them worse in position. Growth of the medial crura will increase tip width

rather than projection along with a retracted columella especially when the second stage is done too early [37]. The four major techniques [18-23] described to place the lower lateral cartilages into normal anatomical position during the primary bilateral cleft nasal reconstruction have their own

drawbacks [31]. McComb's [18,19] technique is a two-staged repair which leaves behind an external scar over the tip of the nose. Mulliken's technique [20,21] leaves the footplates of the medial crura in the depression above the projecting premaxilla associated with the diminutive anterior nasal spine which also prevents adequate approximation of alar bases. The retrograde method [23,24] requires either preoperative or postoperative nasal molding to achieve the maximum benefit. The prolabial blood supply in Trott & Mohan's [22] technique was claimed by opponents to be precarious. However, this approach allows the best possible exposure to the displaced dome cartilages even in the asymmetric forms of bilateral clefts and avoids scars at both the nasal tip & lip-columella junction. It is a technique that does not rely on presurgical orthopaedic / nasoalveolar molding & avoids external scars hence the choice of using it for the patients in this study with some modifications.

Regarding the claim of poor prolabial supply in the open rhinoplasty technique by Trott & Mohan's [22] technique. It has been well established that the philtrum & premaxilla derive their blood supply from only the posterior septal artery & the terminal branches of the anterior ethmoidal artery in the bilateral clefts [38]. The ascending septal branch of the superior labial artery & the greater palatine arteries are both interrupted by the cleft. The terminal branches of the anterior ethmoidal artery pass between the inferior aspect of the medial crura of the lower lateral cartilages into the prolabium [39]. Therefore, extreme care should be taken to preserve these vessels when combining an open tip plasty with alveoloplasty in order to avoid any vascular compromise of the premaxilla & prolabium.

Mueller and coworkers [40] studied the arterial flow velocity & microcirculation and found normal blood supply with no functional intrinsic circulatory deficit in the bilateral cleft lip-cleft palate patients despite the aberrant cleft vascular anatomy. Paramedian prolabial arteries were a constant finding in the BCLP with increased flow in the prolabium indicating a strong hemodynamic need in this territory preoperatively. This higher microcirculation flow remained at the end of their lip repair and in the late postoperative period. They attributed these findings to the intraoperative vessel preservation in the prolabium and advocated strict vascular preservation in cleft surgery. In the technique presented here, the prolabium was elevated off the premaxilla in a deep plane supraperiosteally in order to preserve its vascular supply, which could

explain why we didn't experience any vascular compromise issues nor any healing problems.

The fibroadipose tissue was removed in all four major techniques along with suturing the domes together at the midline are considered keys to a good outcome for the primary bilateral cleft lip & nose repair [12,31]. In the technique presented herein, exposing the tip was done through an open approach staying strictly in a supraperichondreal plane to avoid injury of the terminal branch of the anterior ethmoid vessels. To further ensure adequate blood supply of the prolabial flap, the dissection was done from lateral to medial to guarantee staying in the proper plane. Following complete exposure of the tip, only fibroadipose tissue that is present in-between the domes was conservatively excised to facilitate suturing them together. This is similar to the technique combining Mullikan & Cutting [31].

One other criticism that was given to Trott & Mohan's [22] open rhinoplasty was the continuous incision from the lateral nostril apex down to the bottom of the cupid's bow. This straight line has been interrupted & broken-up in the technique presented here by advancing a small v-flap from the lateral segment of the lip skin into the columella-prolabial flap at the level of columellar base at the nasal sill. This kept the columella slightly wider than the prolabial flap.

Maintaining a wide columella was done similar to Morovic & Cutting [31] in their early cases with open rhinoplasty in order to preserve blood supply. This explains the wider columella in the operated group when compared to their age matched controls. The columellar length was longer in the operated group at three months postoperatively mostly due to tendency to overcorrect them. They become comparable with the age-matched controls later on at six and twelve months post. Similarly, nasal tip projection of these patients were comparable to age matched controls at all time frames in this study. These results are similar to the findings of the combined Cutting and Mullikan method [31].

In conclusion, a well-implemented cheiloalveoloplasty combined with primary open tip-plasty without nasoalveolar molding is cost effective in limiting the number of surgical interventions & combining the advantages of both cheiloalveoloplasty and open rhinoplasty. It stabilizes the alveolar segments and eliminates the occurrence of anterior palatal & alveolar fistulae by providing a two-layer closure. Furthermore, this approach provides optimally oriented nasal tip anatomy while reducing

the social stigma of the bilateral cleft lip nose appearance early during the child's growth.

REFERENCES

- 1- Latham R.A.: Development and structure of the premaxillary deformity in bilateral cleft lip and palate. *Br. J. Plast. Surg.*, 26: 1, 1973.
- 2- King B.F. III, Workman C.H. III and Latham R.A.: An anatomical study of the columella and the protruding premaxilla in a bilateral cleft lip and palate infant. *Cleft Palate J.*, 16: 223, 1979.
- 3- Bardach J., Salyer K. and Noordhoff M.S.: Bilateral cleft lip repair. In Bardach J., Salyer K., eds. *Surgical techniques in cleft lip and palate*. 2nd ed. St. Louis: Mosby Co, 113-172, 1991.
- 4- Fisher D.M. and Mann R.J.: A model for the cleft lip nasal deformity. *Plast. Reconstr. Surg.*, 101: 1448, 1998.
- 5- Panossian A. and Fisher D.M.: Bilateral cleft lip repair. In: Bentz M.L., Bauer B.S., Zuker R.M., eds. *Principles & Practice of Pediatric Plastic Surgery*. St. Louis, Missouri: Quality Medical Publishing, Inc., 455-471, 2008.
- 6- Grayson B.H., Cutting C. and Wood R.: Preoperative columella lengthening in bilateral cleft lip and palate. *Plast. Reconstr. Surg.*, 92: 1422, 1993.
- 7- Morovic C., Monasterio L. and Ford A.: Primary repair of bilateral cleft lip nose: A comparison between open rhinoplasty techniques (Trott versus Cutting). In *Proceedings of the 9th International Congress on Cleft Palate and Related Craniofacial Anomalies*. Goteborg, Sweden, 2001.
- 8- Grayson B.H. and Garfinkle J.S.: Nasoalveolar molding and columella elongation in preparation for the primary repair of unilateral and bilateral cleft lip and palate. In Losee J.E., Kirschner R.E., eds. *Comprehensive cleft care*. New York: McGraw-Hill, 701-720, 2009.
- 9- Mulliken J.B.: Combining the Cutting and Mulliken methods for primary repair of the bilateral cleft lip nose. *Discussion. Plast. Reconstr. Surg.*, 116 (6): 1620, 2005.
- 10- Liou E.J., Subramanian M. and Chen P.K.: Progressive changes of columella length and nasal growth after nasoalveolar molding in bilateral cleft patients: A 3-year follow-up study. *Plast. Reconstr. Surg.*, 119: 642, 2007.
- 11- Lee C.T., Garfinkle J.S., Warren S.M., Brecht L.E., Cutting C.B. and Grayson B.H.: Nasoalveolar molding improves appearance of children with bilateral cleft lip-cleft palate. *Plast. Reconstr. Surg.*, 122: 1131, 2008.
- 12- Henry C., Samson T. and Mackay D.: Evidence-based medicine: The cleft lip nasal deformity. *Plast. Reconstr. Surg.*, 133: 1276, 2014.
- 13- Millard D.R.: Bilateral cleft lip and a primary forked flap: a preliminary report. *Plast. Reconstr. Surg.*, 39 (1): 59, 1967.
- 14- Millard D.R.: Closure of bilateral cleft lip and elongation of columella by two operations in infancy. *Plast. Reconstr. Surg.*, 47 (4): 324, 1971.
- 15- Mulliken J.B.: Repair of bilateral complete cleft lip and nasal deformity. *Cleft Palate Craniofac J.*, 37 (4): 342, 2004.
- 16- Kramer F.J., Gruber R., Fialka F., Sinikovic B. and Schliephake H.: Quality of life in school-age children with orofacial clefts and their families. *J. Craniofac. Surg.*, 20: 2061, 2009.
- 17- Kramer F.J., Gruber R., Fialka F., et al.: Quality of life and family functioning in children with non-syndromic orofacial clefts at preschool ages. *J. Craniofac. Surg.*, 19: 580, 2008.
- 18- McComb H.: Primary repair of the bilateral cleft lip nose. *Br. J. Plast. Surg.*, 28: 262, 1975.
- 19- McComb H.: Primary repair of the bilateral cleft lip nose: A 15-year review and a new treatment plan. *Plast. Reconstr. Surg.*, 86: 882, 1990.
- 20- Mulliken J.B.: Correction of the bilateral cleft lip nasal deformity: Evolution of a surgical concept. *Cleft Palate Craniofac J.*, 29: 540, 1992.
- 21- Mulliken J.B.: Bilateral complete cleft lip and nasal deformity: An anthropometric analysis of staged to synchronous repair. *Plast. Reconstr. Surg.*, 96: 9, 1995.
- 22- Trott J.A. and Mohan N.: A preliminary report on one stage open tip rhinoplasty at the time of the lip repair in bilateral cleft lip and palate: The Alor Setar experience. *Br. J. Plast. Surg.*, 46: 215-222, 1993.
- 23- Cutting C., Grayson B., Brecht L., et al.: Presurgical columellar elongation and primary retrograde nasal reconstruction in one-stage bilateral cleft lip and nose repair. *Plast. Reconstr. Surg.*, 101: 630, 1998.
- 24- Talmant J.: Current trends in the treatment of bilateral cleft lip and palate. *Oral Maxillofac. Surg. Clin. North Am.*, 12: 1, 2000.
- 25- Thomas C.: Primary rhinoplasty by open approach with repair of bilateral complete cleft lip. *J. Craniofac. Surg.*, 20 (2): 1715, 2009.
- 26- Allori A.C. and Marcus J.R.: Modern tenets for repair of bilateral cleft lip. *Clin. Plast. Surg.*, 41 (2): 179, 2014.
- 27- Khosla R.K., McGregor J., Kelley P.K. and Gruss G.S.: Contemporary concepts for the bilateral cleft lip and nasal repair. *Semin Plast. Surg.*, 26 (4): 156, 2012.
- 28- Monson L.A., Kirschner R.E. and Losee J.E.: Primary repair of cleft lip and nasal deformity. *Plast. Reconstr. Surg.*, 132: 1040e, 2013.
- 29- Nakajima T., Ogata H. and Sakuma H.: Long-term outcome of simultaneous repair of bilateral cleft lip & nose (a 15 year experience). *Br. J. Plast. Surg.*, 56 (3): 205, 2003.
- 30- Anthony W., Rami G. and Martha M.: Use of staged rotation-advancement procedures for the treatment of incomplete bilateral clefts of the lip. *Ann. Plast. Surg.*, 52 (3): 263, 2004.
- 31- Morovic C.G. and Cutting C.: Combining the Cutting and Mulliken methods for primary repair of the bilateral cleft lip nose. *Plast. Reconstr. Surg.*, 116: 1613, 2005.
- 32- McComb H.K.: Primary repair of the bilateral cleft lip nose: A long-term follow-up. *Plast. Reconstr. Surg.*, 124 (5): 1610, 2009.
- 33- Xu H., Salyer K.E. and Genecov E.R.: Primary bilateral one-stage cleft lip/nose repair: 40-year Dallas experience: Part I. *J. Craniofac. Surg.*, 20 (Suppl 2): 1913, 2009.

- 34- Garfinkle J.S., King T.W., Grayson B.H., Brecht L.E. and Cutting C.B.: A 12-year anthropometric evaluation of the nose in bilateral cleft lip-cleft palate patients following nasoalveolar molding and Cutting bilateral cleft lip and nose reconstruction. *Plast. Reconstr. Surg.*, 126: 1659, 2011.
- 35- Badran H.A., Ali H.M. and Elbarbary A.S.: Personal technique for primary repair of alveolar clefts. *Craniomaxillofac Trauma Reconstr.*, 5: 51-58, 2012.
- 36- Mulliken J.B., Burvin R. and Farkas L.G.: Repair of bilateral complete cleft lip: Intraoperative nasolabial anthropometry. *Plast. Reconstr. Surg.*, 107 (2): 307-14, 2001.
- 37- Cutting C., McComb H. and Mulliken J.: Virtual surgery; volume II: Bilateral cleft: The smile train. New York: Smile Train, 2001.
- 38- Slaughter W.B., Henry J.W. and Berger J.C.: Changes in blood vessel patterns in bilateral cleft lip. *Plast. Reconstr. Surg.*, 26 (2): 160-79, 1960.
- 39- Bennum R. and Dogliotti P.: Anatomical basis for one-stage repair of bilateral cleft lip. In *Proceedings of the European Association for Maxillofacial Surgery*, Madrid, Spain, December 16-17, 1986.
- 40- Mueller A.A., Schumann D., Reddy R.R., Schwenzer-Zimmerer K., Mueller-Gerbl M., Zeilhofer H.F., Sailer H.F. and Reddy S.G.: Intraoperative vascular anatomy, arterial blood flow velocity, and microcirculation in unilateral and bilateral cleft lip repair. *Plast. Reconstr. Surg.*, 130: 1120, 2012.